

Cutaneous Angiosarcoma of the Scalp Aggravated after Hair Dyeing Presenting as Bilateral Facial Cellulitis: A Case Report

Si Hyun Kwak¹ , Da Woon Lee¹ , Jun Hyuk Kim¹ , Hwan Jun Choi^{1,2} 

¹Department of Plastic and Reconstructive Surgery, Soonchunhyang University College of Medicine, Cheonan, Korea

²Institute of Tissue Regeneration, Soonchunhyang University College of Medicine, Cheonan, Korea

Abstract

Angiosarcoma is a rare and aggressive soft tissue sarcoma. The cutaneous form of angiosarcoma occurs most commonly in the head and neck region, especially the scalp. Because of its aggressiveness and tendency for distant metastasis and local recurrence, early diagnosis of angiosarcoma is critical. We report a case of cutaneous angiosarcoma of the scalp aggravated by hair dyeing. In this case, it presented as bilateral facial cellulitis because of the progression of an infection. The patient was not aware of his malignant lesions on the scalp since they are typically hidden. Meanwhile, infection caused by chemical stimulation from hair dye exacerbated the lesions. However, an early incisional biopsy revealed angiosarcoma with metastasis to the lymph nodes and parotid glands, leading the patient to appropriate chemotherapy. In conclusion, the variable and non-specific findings of cutaneous angiosarcoma can delay the diagnosis; thus, the importance of an excisional or incisional biopsy, which can result in early diagnosis when suspecting malignancy, is highlighted.

Keywords: Case reports; Cellulitis; Hair dyes; Hemangiosarcoma; Scalp

Introduction

Angiosarcoma is a rare soft tissue sarcoma accounting for less than 2% of all soft tissue sarcomas [1]. It is an aggressive malignant neoplasm originating from the endothelial cells of blood or lymphatic vessels. While it occurs most commonly in the head and neck region, it can be located in any anatomical site of the body [1,2]. The cutaneous form of angiosarcoma is characterized by diffuse and ill-defined margins, which complicate surgical management [3,4]. It is also associated with a high rate of local recurrence and distant metastasis to other organs [5]. The extensive skin and subcutaneous tissue involvement is due to its tendency toward horizontal spread, with progression of the tumor along vascular structures [1,6]. For these reasons, cutaneous angiosarcoma has poor prognosis with a 5-year survival rate ranging from 30% to 40% [7]. Aiming at a clinical demonstration of this rare tumor, we report a case of cutaneous angiosarcoma located in the scalp, presenting as facial cellulitis which was aggravated by hair dyeing. The report was approved by the Institutional Review Board of Soonchunhyang University Hospital (IRB No. 2021-02-051) and informed consent for publication of the study was obtained from the patient.

Case

We report a case of a 55-year-old male patient who had no significant past medical history. Since he had dyed his hair 3 months before his visit, an ulcerated lesion with tur-

Case Report

Received: July 20, 2023

Revised: September 30, 2023

Accepted: October 3, 2023

Corresponding author:

Hwan Jun Choi, MD, PhD

Department of Plastic and Reconstructive Surgery, Soonchunhyang University College of Medicine, 31 Suncheonhyang 6-gil, Dongnam-gu, Cheonan 31151, Korea
E-mail: medi619@hanmail.net

This is an Open Access article distributed under the terms of the Creative Commons Attribution Non-Commercial License (<https://creativecommons.org/licenses/by-nc/4.0/>) which permits unrestricted non-commercial use, distribution, and reproduction in any medium, provided the original work is properly cited.

© 2023 Korean Wound Management Society

bid discharge occurred on his scalp. He came to the emergency room because of bilateral swelling and redness of the whole face with a 15×10 cm-sized ulcerative scalp wound that had gradually grown in size (Fig. 1). The patient had been treated with oral antibiotics for 2 weeks after a single dose of empirical intra-

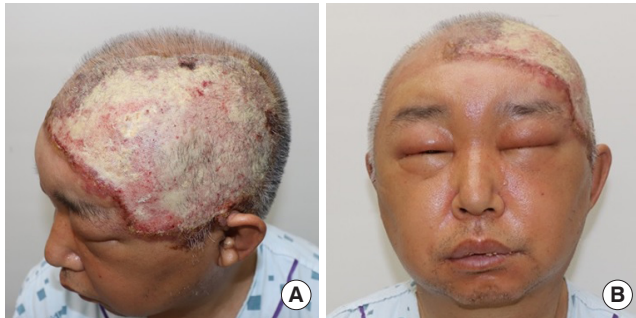

Fig. 1. Initial photographic findings. (A) A 15×10 cm-sized raw surface is on the left parietal area of the scalp with turbid discharge and yellowish sludge. (B) The patient had swelling on his entire face with both periorbital areas displaying redness.

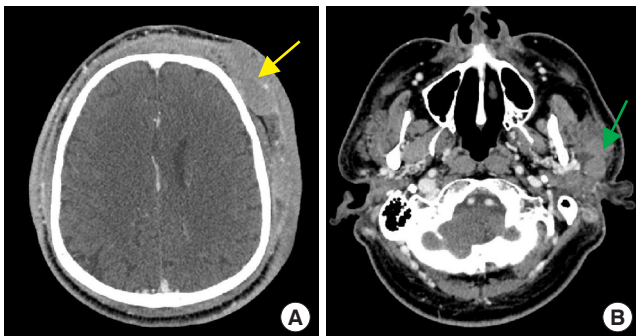


Fig. 2. Facial computed tomographic findings. (A) Diffuse soft tissue attenuated swelling and mass-like formation (yellow arrow) is identified in the left frontoparietal scalp. (B) Multiple heterogeneous enhancing nodules of different sizes (green arrow) are located in the left parotid gland.

venous cefazoline in a local clinic. Nevertheless, the lesion worsened and the patient was admitted to the department of infectious medicine and given terbinafine 250 mg per day for a week for a possible tinea capitis or another fungal infection. However, there was no improvement in his facial swelling and redness. On facial enhanced computed tomography (CT), several potentially malignant lymph nodes and parotid gland enlargement were found together with the bilateral facial cellulitis (Fig. 2). Under general anesthesia, incisional biopsy was performed from multiple sites on the scalp skin, parotid gland tissue and parotid lymph nodes (Lt level VIII) (Fig. 3). Debride-

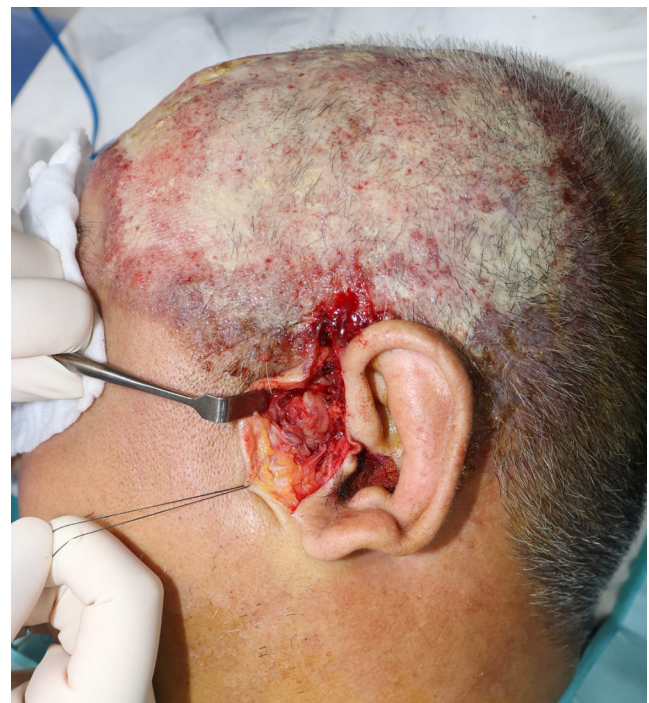

Fig. 3. Intraoperative photographic findings. An ill-defined nodule is identified around the parotid gland.

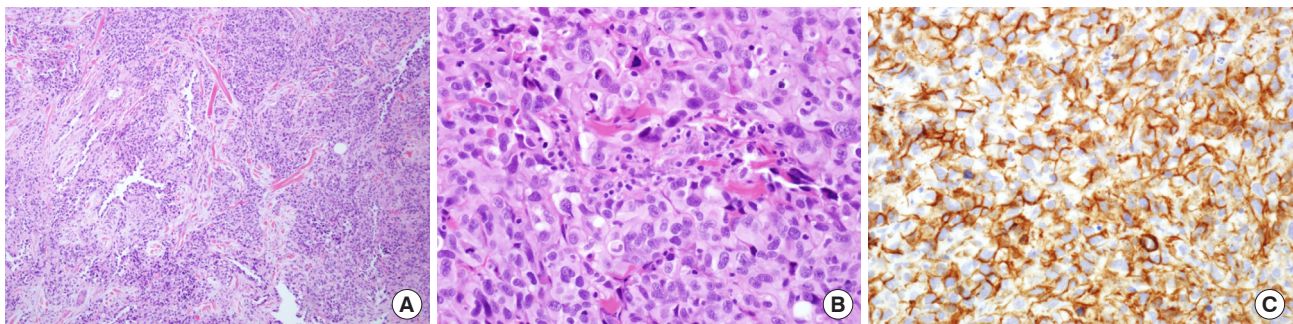


Fig. 4. Pathologic findings. (A) Spaces in the form of vascular channels are identified (hematoxylin and eosin [H&E] stain, ×100). (B) The tumor shows diffused high-grade pleomorphism and atypical mitosis (H&E stain, ×400). (C) Immunohistochemistry examination of the tumor display high expression of CD31, an endothelial cell marker (×400).

ment of inflammatory and unhealthy tissue was also carried out with bacterial culture of the inflamed tissue around the suspected cancer lesions on the scalp and preauricular area.

After surgical debridement with multiple incisional biopsies, a diagnosis of scalp angiosarcoma with metastasis to parotid gland and lymph nodes was confirmed (Fig. 4). *Stenotro-*

phomonas maltophilia and *Helcococcus kunzii*, opportunistic infections that can occur in immunosuppressed patients, were identified from bacterial cultures of inflamed tissue [8,9]. For staging workup, magnetic resonance imaging (MRI) of the neck was performed, revealing multiple enlarged lymph nodes suspicious of malignancy in the parotid gland and both level II and V of the neck. No distant metastasis other than in the head and neck region were identified on positron emission tomography-CT, chest CT, abdominopelvic CT, and bone scan (Fig. 5). Considering the stage and unresectable status of the cancer, chemotherapy was planned, and the wound of the scalp lesion was managed conservatively by daily dressings with antibiotic topical agent and foam. Although the facial

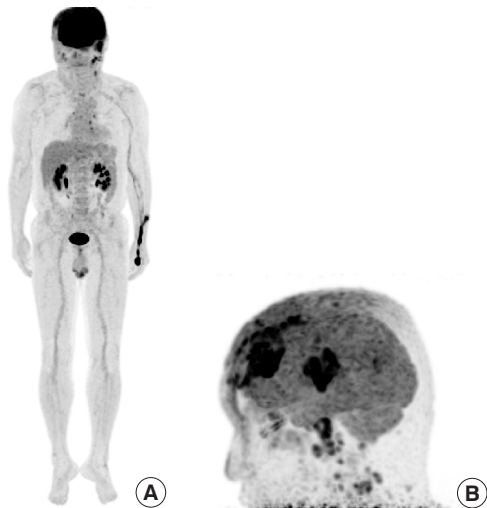


Fig. 5. Positron emission tomography-computed tomography (PET-CT) images. (A) While there were no distant metastasis findings on PET-CT, (B) fluorodeoxyglucose (FDG) uptake in the frontoparietal area and temporal area indicated malignancy involvement.

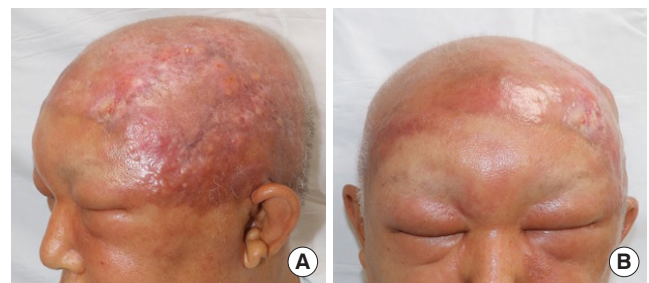


Fig. 7. Postoperative photographic findings 3 months after surgery. (A) The wound was stabilized and progressed to epithelization. (B) The facial swelling did not show distinct improvement.

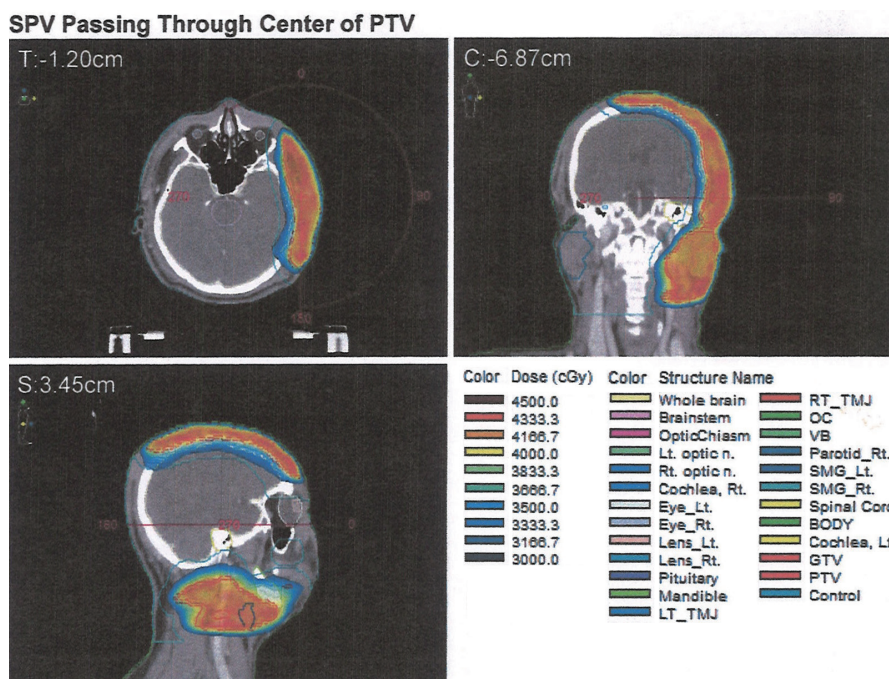


Fig. 6. Palliative radiation therapy report. It shows the distribution of radiation by anatomical locations.

swelling improved only slightly, the wound infection stabilized, and the patient was discharged.

Following up for outpatient treatment, chemotherapy with paclitaxel was performed for 12 weeks as a first line therapy. Additionally, palliative radiotherapy consisting of 4.0 to 5.0 Gy per fraction with a total dose of 65 Gy to the scalp lesion and left cheek was performed (Fig. 6). Although facial swelling persisted, the scalp wound was stabilized without any discharge (Fig. 7). Afterwards, second-line chemotherapy using adriamycin was performed three times with palliative radiotherapy involving 4.0 Gy per fraction with a total dose of 60 Gy. Ulcerative lesions due to irradiation reoccurred on the scalp but were successfully managed with self-dressings using foam.

Discussion

Angiosarcoma is a highly aggressive malignant tumor originating from vascular endothelial cells, which takes up below 2% of all soft tissue sarcomas [1]. It ranges from well-differentiated tumors which have inherent properties of normal epithelium to poorly differentiated tumors [6]. While angiosarcoma can originate from any anatomical location including skin, soft tissue, bone, breast, and other visceral organs, it manifests dominantly as cutaneous lesions [10]. Although most soft tissue sarcomas are located in the deep layer of soft tissue under the skin, angiosarcoma mainly presents at the dermis and may extend to the superficial soft tissue [6,7].

The cutaneous form of angiosarcoma most commonly occurs in the head and neck region, especially the scalp. The clinical appearance of cutaneous angiosarcomas varies greatly according to individual cases. It is necessary to differentiate cutaneous angiosarcoma from other types of skin cancer such as melanoma or squamous cell carcinoma considering its non-specific morphologic properties [11,12]. Cutaneous angiosarcoma can manifest as a single lesion or multiple lesions; with a bluish or violaceous color; including nodules, plaques, or flat infiltrating areas; and is occasionally accompanied by bleeding or ulceration [4,5]. In the early stages, it usually occurs with the clinical appearance of a bruise-like lesion with an indistinct border, but in advanced lesions, it can progress to being nodular, elevated, or ulcerated [6]. On the scalp, early lesions can be hidden in the hair, making early detection difficult [13]. Thus, as the primary lesion aggressively progresses, it could be mistaken for tinea capitis or facial cellulitis due to infection accompanying the cancerous lesion or lymphedema in sur-

rounding tissues [3,6]. Being an immigrant from China, this particular patient made a delayed visit to the hospital because his status rendered health care less accessible. The infection of the scalp lesion was quite advanced, leading to facial cellulitis, and this confused the diagnosis. Furthermore, the patient had applied hair dye without being aware that a malignant cutaneous lesion was in his scalp. More than three-fourths of hair dye products are oxidizing agents which irritate the skin and can even cause infections such as contact dermatitis in severe cases. It is possible that the patient had cutaneous angiosarcoma lesions with raw surfaces, which were made worse by irritation from the hair dye. Because enhanced facial CT revealed abnormal findings in the lymph nodes, we performed excisional biopsies in multiple sites involving the primary scalp lesion.

In this case, angiosarcoma was confirmed on biopsies of the skin of scalp and parotid gland, which was FNCLCC (Fédération Nationale des Centres de Lutte Contre Le Cancer) grade 3. Immunohistochemical staining results were positive for CD34 and CD31 with 70% to 80% of Ki-67. Enhanced neck MRI indicated multiple metastatic lymph nodes in the parotid gland and both sides of the neck. It was difficult to resect all of the cancerous lesions as they were widely dispersed on the scalp with regional metastasis to the cervical lymph nodes and parotid gland. Chemotherapy with paclitaxel was performed as first-line therapy over a duration of 12 weeks. Severe swelling due to lymphedema of the whole face necessitated palliative radiation therapy. Follow-up radiological examination was performed every 3 months, and second-line chemotherapy with adriamycin was administered with the palliative radiation therapy. During this period, the patient was receiving regular dressings for the primary ulcerative scalp lesion. In the process, the lesion worsened due to irradiation, but gradually improved with foam dressings.

In conclusion, the varied appearance of cutaneous cancerous lesions of the scalp complicates early detection, as does its anatomical location which is covered with hair follicles [1]. Additionally, cutaneous cancerous lesions on the scalp can be mistaken as facial cellulitis, because they can progress aggressively with lymphedema in surrounding tissues and infection of the cancerous lesions. This applies to malignant skin tumors like squamous carcinoma cell or basal cell carcinoma as well as cutaneous angiosarcoma, suggesting that scalp lesions need to be carefully observed. Finally, it should be noted that soft tissue sarcomas are aggressive; this case demonstrates the importance of excisional or incisional biopsy for early detection of primary cutaneous angiosarcoma and the possibility of its

misdiagnosis as facial cellulitis after infectious events such as using hair dye.

Conflict of interest

This work was supported by the National Research Foundation of Korea (NRF) grant funded by the Korea government (MSIT) (2020R1A2C1100891) and was supported Soonchunhyang University Research Fund. No other potential conflicts of interest relevant to this article were reported.

ORCID iDs

Si Hyun Kwak <https://orcid.org/0000-0001-9594-700X>
Da Woon Lee <https://orcid.org/0000-0002-6969-5643>
Jun Hyuk Kim <https://orcid.org/0000-0002-0266-8480>
Hwan Jun Choi <https://orcid.org/0000-0002-0752-0389>

References

1. Rampinelli H, Ramos-e-Silva M, Quintella DC, et al. Cutaneous angiosarcoma. *Case Rep Dermatol* 2018;10:55-60.
2. Fujimoto M, Kiyosawa T, Murata S, et al. Vascular endothelial growth factor in angiosarcoma. *Anticancer Res* 1998;18:3725-9.
3. Budd GT. Management of angiosarcoma. *Curr Oncol Rep* 2002;4:515-9.
4. Morrison WH, Byers RM, Garden AS, et al. Cutaneous angiosarcoma of the head and neck: a therapeutic dilemma. *Cancer* 1995;76:319-27.
5. Macias-Garcia L, Lara-Bohorquez C, Jorquera-Barquero E, et al. Recurrent cutaneous angiosarcoma of the scalp with aberrant expression of S100: a case report. *Am J Dermatopathol* 2018;40:419-22.
6. Pawlik TM, Paulino AF, McGinn CJ, et al. Cutaneous angiosarcoma of the scalp: a multidisciplinary approach. *Cancer* 2003;98:1716-26.
7. Cao J, Wang J, He C, et al. Angiosarcoma: a review of diagnosis and current treatment. *Am J Cancer Res* 2019;9:2303-13.
8. Brooke JS. *Stenotrophomonas maltophilia*: an emerging global opportunistic pathogen. *Clin Microbiol Rev* 2012;25:2-41.
9. Lotte R, Lotte L, Degand N, et al. Infectious endocarditis caused by *Helcococcus kunzii* in a vascular patient: a case report and literature review. *BMC Infect Dis* 2015;15:238.
10. Ito T, Uchi H, Nakahara T, et al. Cutaneous angiosarcoma of the head and face: a single-center analysis of treatment outcomes in 43 patients in Japan. *J Cancer Res Clin Oncol* 2016;142:1387-94.
11. Suk S, Shin HW, Yoon KC, et al. Aggressive cutaneous squamous cell carcinoma of the scalp. *Arch Craniofac Surg* 2020;21:363-7.
12. Jung JH, Jeon YR, Kim HI, et al. Verrucous carcinoma arising from actinic keratosis: a case report. *Arch Craniofac Surg* 2021;22:333-6.
13. Guadagnolo BA, Zagars GK, Araujo D, et al. Outcomes after definitive treatment for cutaneous angiosarcoma of the face and scalp. *Head Neck* 2011;33:661-7.